

A right perisylvian neural network for human spatial orienting

Hans-Otto Karnath

Section of Neuropsychology, Center of Neurology, Hertie-Institute for Clinical Brain Research, University of Tübingen, Tübingen, Germany

Chapter 17 in: M. S. Gazzaniga (ed.) *The Cognitive Neurosciences IV*. Cambridge, Mass.: MIT Press, p. 259-268.

Abstract

Homologous neural networks seem to exist in the human left and right hemispheres tightly linking cortical regions straddling the sylvian fissure. White matter fiber bundles connect the inferior parietal lobule with the ventrolateral frontal cortex, ventrolateral frontal cortex with superior/middle temporal cortex, and superior/middle temporal cortex with the inferior parietal lobule. It is argued that these perisylvian networks serve different cognitive functions, a representation for language and praxis in the left hemisphere and a representation for processes involved in spatial orienting in the right. The tight perisylvian anatomical connectivity between superior/middle temporal, inferior parietal and ventrolateral frontal cortices might explain why lesions at these distant cortical sites around the sylvian fissure in the human right hemisphere can lead to the same disturbance of orienting behavior, namely to spatial neglect.

In recent years, it has been shown that functional and structural lateralization of the brain is more widespread among vertebrates than previously believed. Nevertheless, it is still appropriate that many motor, sensory, visual, but also cognitive functions show bihemispheric representations in the human and non-human primate. Only few (so-called 'higher') cognitive functions have obvious asymmetrical representations. Among them are language, praxis, and spatial orienting. While an elaborate representation for language and praxis has evolved in the human left hemisphere, a neural system involved in spatial orienting is dominantly represented in the right hemisphere. Consequently, locally corresponding damage to one of the two hemispheres leads to different symptoms. While the dominant disorders in neurological patients with left hemisphere involvement are aphasia and apraxia, patients with right hemisphere damage typically show spatial neglect. The latter describes a spontaneous deviation of the eyes and the head towards the ipsilesional, right side (Fruhmann-Berger and Karnath, 2005; Fruhmann-Berger et al., 2006). Patients with such a disorder disregard objects located on the contralesional, left side. When e.g. searching for targets, copying, or reading they concentrate their exploratory movements predominantly on the right side of space (Heilman et al., 1983; Behrmann et al., 1997; Karnath et al., 1998). The question thus arises whether the development of these different functions in the human left and right hemispheres corresponds with different anatomical representations. Or is it possible that homologous neural structures serve as correlates for language and praxis in the left and for spatial orientation in the right hemisphere?

Three major cortical areas have been described as neural correlates of spatial neglect in the human right hemisphere. A first study by Heilman and co-workers (1983) revealed the right inferior parietal lobule (IPL) and the temporo-parietal junction (TPJ). Subsequent studies reported comparable observations (e.g. Vallar and Perani, 1986; Mort et al., 2003). Lesions located in the right ventrolateral frontal cortex were also observed to correlate with spatial neglect (Vallar and Perani, 1986; Husain and Kennard, 1996; Committeri et al., 2007). Finally, several studies have revealed the right superior temporal cortex and adjacent insula as being critically related to the disorder (Karnath et al., 2001, 2004; Buxbaum et al., 2004; Corbetta et al., 2005; Committeri et al., 2007; Sarri et al., 2009).

Interestingly, a similar pattern of perisylvian correlates have been observed in the human left hemisphere when stroke patients suffer from aphasia. Early analyses (e.g., Kertesz et al., 1979; Poeck et al., 1984) as well as more recent studies of cortical lesion localisation in neurological patients with disorders in language comprehension and/or speech production (e.g., Kreisler et al., 2000; Dronkers et al., 2004; Borovsky et al., 2007) revealed involvement

of the ventrolateral frontal cortex, superior and middle temporal gyri, insula, and the IPL. These findings are supported by electrical mapping of the human cortex during surgery in awake patients as well as functional magnetic resonance imaging (fMRI) in healthy subjects. A recent meta-analysis of 129 fMRI studies on phonological, semantic, and syntactic processing revealed activation in distributed areas predominantly involving left middle and inferior ventrolateral frontal, superior and middle temporal, as well as inferior parietal cortices (Vigneau et al., 2006). These sites correspond very well with those in which intraoperative cortical stimulation evoked disturbances of language processes, such as anomia, alexia, or speech arrest (e.g., Boatman, 2004; Duffau et al., 2005; Sanai et al., 2008).

These perisylvian brain areas in the human left hemisphere do not appear to represent language processes solely. Recent analyses of lesion localisation in patients suffering from apraxia suggested that they are also involved in the organisation of motor actions (Goldenberg and Karnath 2006; Goldenberg et al., 2007). Stroke patients with either disturbed pantomime of tool use or with disturbed imitation of finger postures typically showed damage of the left inferior frontal gyrus (IFG) and adjacent portions of the insula, while disturbed imitation of hand postures was associated with posterior lesions affecting the IPL and TPJ. This close anatomical relationship between the representation of praxis on the one hand and language on the other led to the assumption that these left perisylvian areas might represent an observation/execution matching system providing the bridge from 'doing' to 'communicating' (Rizzolatti and Arbib 1998; Iacoboni and Wilson 2006). Its development was seen as a consequence of the fact that before speech appearance the precursors of these areas in the monkey were endowed with a mechanism for recognizing actions made by others. This mechanism was seen as the neural prerequisite for the development of interindividual communication and finally of speech (Rizzolatti and Arbib 1998).

Thus, it seems as if very similar anatomical cortical areas straddling the sylvian fissure are involved in representing language and praxis in the human left hemisphere and spatial orienting in the right hemisphere. Recent anatomical studies have revealed that a dense white matter connectivity exists specifically between these perisylvian cortical areas. In the following, it will be argued that intimately interconnected homologous perisylvian networks have evolved in the human left and right hemispheres serving for different cognitive functions, a representation for language and praxis in the left hemisphere and a representation for spatial orienting in the right hemisphere. Further, it will be argued that for these cognitive processes the functioning of the perisylvian cortical areas is critical, not the mere disconnection of their white matter interconnections.

Dense perisylvian white matter connectivity

Beyond traditional axonal tract tracing and myelin staining techniques, the development of diffusion-based imaging, e.g. diffusion tensor and diffusion spectrum imaging (DTI / DSI), has opened new opportunities for identifying long range white matter pathways. By combining the findings from DSI and from histological tract tracing, Schmahmann and colleagues separated ten long, bidirectional association fiber bundles in the monkey brain (Schmahmann and Pandya 2006; Schmahmann et al., 2007). Anatomical homologies have been described in the human with the aid of diffusion-based imaging *in vivo* (e.g., Catani et al., 2002; 2005, 2007; Makris et al., 2005, 2007; Mori et al., 2005; Upadhyay et al., 2008) and myelin staining *post-mortem* (Bürgel et al., 2006). In the following, the focus will be on those pathways that connect the perisylvian cortical areas, i.e. the superior/middle temporal, inferior parietal, and ventrolateral frontal cortices – where damage has been shown to provoke spatial neglect in the case of right brain lesions and aphasia and/or apraxia after left hemisphere involvement.

In the monkey and human, the superior longitudinal fasciculus (SFL) is the major cortical association fiber pathway linking parietal and frontal cortices. It is subdivided into different, separable components (Petrides and Pandya 1984; Makris et al., 2005; Schmahmann et al., 2007). One part – the SLF I – is situated dorsally of the perisylvian network area, connecting the superior parietal lobule with dorsal premotor areas. Two further subcomponents connect the IPL with premotor and prefrontal cortices. The SLF II links the IPL and intraparietal sulcus with the posterior and caudal prefrontal cortex, while the SLF III connects the rostral IPL with the ventral part of premotor and prefrontal cortex. A further fiber tract that is separable from these connections stems from the caudal part of the superior/middle temporal gyrus (STG/MTG), arches around the caudal end of the sylvian fissure, and extends to the lateral prefrontal cortex along with the SLF II fibers. This latter fiber tract is termed the arcuate fasciculus (AF) and has been described in human (Burdach, 1819-26; Dejerine and Dejerine-Klumpke 1895; Catani et al., 2002, 2005; Makris et al., 2005; Vernooij et al., 2007; Upadhyay et al., 2008) as well as in monkey (Petrides and Pandya, 1988; Schmahmann et al., 2007). Some disagreement exists related to whether or not this fiber bundle is regarded a fourth subdivision of the SLF (SLF IV; Makris et al., 2005; Vernooij et al., 2007), a stand-alone connection adjacent to the SLF (Schmahmann et al., 2007), or only part, namely the long segment (see below), of a three-way AF structure (Catani et al., 2005).

A fiber bundle situated in close proximity to the SLF II and the AF is the superior occipitofrontal fasciculus (SOF), also termed the '(superior) frontooccipital fasciculus' ([S]FOF) by some authors. The SOF forms the medial border of the corticospinal tract and separates it from the lateral ventricles. The fibers run parallel to the dorsolateral margin of the lateral ventricles below the corpus callosum. Some of its fibers intermingle with SLF II and AF fibers. Different from expectations based on its labeling, the SOF not only connects occipital but also inferior parietal with frontal lobe areas. In the monkey as well as in humans, this long association bundle bidirectionally extends from the IPL and dorsomedial parastriate occipital cortex to caudal, dorsal, and medial frontal lobe areas (Catani et al., 2002; Bürgel et al., 2006; Makris et al., 2007; Schmahmann et al., 2007).

Two further, ventrally located fiber bundles contribute to the perisylvian network focussed on in this chapter, namely the strong pathway running through the extreme capsule (EmC) and the middle longitudinal fasciculus (MdLF). Both bundles have been described in monkeys (Seltzer and Pandya, 1984; Schmahmann and Pandya, 2006; Schmahmann et al., 2007; Petrides and Pandya, 2007) as well as in humans (Makris and Pandya, 2009; Makris et al., 2009). The EmC is situated between the claustrum and the insular cortex interconnecting the inferior frontal and orbitofrontal gyri with the mid-portion of the superior temporal region. It further continues caudally toward the occipital cortex and toward the IPL, flanking here another fiber pathway, namely the MdLF (Makris and Pandya, 2009; Makris et al., 2009). The MdLF is a fiber bundle that runs within the white matter of the superior temporal gyrus extending from the IPL to the temporal pole. Although there is no common agreement yet, it appears as if the EmC corresponds with the bundle termed 'inferior occipitofrontal fasciculus (IOF)' [also 'inferior frontooccipital fasciculus' (IFOF)] by other authors (Nieuwenhuys et al. 1988, Catani et al. 2002, Kier et al., 2004; Wakana et al., 2004; Bürgel et al. 2006).

For clarification it should be pointed out that Catani and colleagues used a different terminology when they investigated the long perisylvian association fibers of the human left hemisphere (Catani et al., 2002, 2005, 2007). The SLF and AF historically have been regarded as a single fiber bundle in the human (Burdach, 1819-26; Dejerine and Dejerine-Klumpke 1895). The terms 'superior longitudinal fasciculus' and 'arcuate fasciculus' thus often were and still are used interchangeably by some authors, including Catani and co-workers. However, despite the different terminology, Catani et al. (2005) also found a long and two shorter segments between the superior/middle temporal, inferior parietal, and ventrolateral frontal cortices (Fig. 17.1a). Tractography reconstruction for a group of 11 healthy subjects revealed a direct connection between the left ventrolateral frontal and the superior/middle

temporal cortex, i.e. between Broca's and Wernicke's language areas. In addition, two shorter pathways were found connecting superior/middle temporal with the inferior parietal cortex ('posterior segment') and the inferior parietal with the dorsolateral frontal cortex ('anterior segment'). There is no doubt that the long connection between the superior/middle temporal and inferior frontal cortex represents the fiber bundle that has been termed 'AF' in the work of other groups (Petrides and Pandya 1988; Makris et al., 2005; Schmahmann et al., 2007; Upadhyay et al., 2008). The 'anterior segment' between the inferior parietal and inferior frontal cortex most probably represents the fiber bundle(s) that have been termed SLF II – maybe in combination with the SLF III and/or SOF. The 'posterior segment' between the superior temporal and inferior parietal cortex had been assumed to represent the MdLF (Schmahmann et al., 2007). However, the recent work by Makris et al. (2009) in the human rather argues that the MdLF is distinct from and located medial to the SLF-AF fibers.

----- Figure 17.1 around here -----

To analyse the perisylvian connectivity between the superior/middle temporal, inferior parietal, and ventrolateral frontal cortices in the human right hemisphere, Gharabaghi and co-workers (2009) investigated twelve right-handed male subjects without neurological deficits by using the same procedure that Catani et al. (2005) applied for the left hemisphere analysis. Figure 17.1b shows the averaged tractography reconstruction obtained from this DTI analysis. It revealed a pattern of fiber connections that largely corresponded to the one demonstrated by Catani et al. (2005) in the human left hemisphere (Fig. 17.1a). While Gharabaghi and co-workers were conducting this analysis, Catani and colleagues published a study (Catani et al., 2007) in which they also had analysed the perisylvian connectivity in the human right hemisphere. In line with the findings illustrated in Figure 17.1b, they found an indirect connection with a posterior segment connecting the superior/middle temporal with the inferior parietal cortex and an anterior segment running from the inferior parietal to the dorsolateral frontal cortex. In contrast, they found the long, direct segment between the superior/middle temporal and the lateral frontal cortices only in about 40% of their individuals, while this segment was present in all subjects (100%) studied by Gharabaghi et al. (2009). Likewise, some studies observed largely symmetrical conditions between the human hemispheres for volume, bundle density, and location of the left- and right-sided AF and SLF (Makris et al., 2005; Bürgel et al., 2006; Upadhyay et al., 2008), while discrepant observations have also been reported (Powell et al., 2006; Vernooij et al., 2007; Glasser and Rilling, 2008). Possible

reasons for the discrepancy between these studies can be attributed to differences in fiber tracking methods, in the choice of the seeding ROIs, and/or the composition of subject samples. Future studies will have to clarify this issue. However, beyond the discrepant observations regarding the long, dorsally located direct connection via the AF, it is undisputed that the superior/middle temporal, lateral frontal and inferior parietal cortices show dense direct (via the EmC/IOF) as well as indirect interconnectivity.

To summarise the hitherto existing findings from tract tracing, myelin staining, and diffusion-based imaging techniques, a dense perisylvian network seems to exist in both hemispheres connecting the inferior parietal lobule with the ventrolateral frontal cortex (via SLF II, SLF III, SOF), ventrolateral frontal cortex with superior/middle temporal cortex (via AF, EmC/IOF), and superior temporal cortex with the inferior parietal lobule (via MdLF, EmC/IOF). Figure 17.2 illustrates these tightly connected perisylvian neural networks.

----- Figure 17.2 around here -----

Functional role of the perisylvian network in the human right hemisphere

There is no disagreement that the perisylvian network in the human left hemisphere is involved in language processes (e.g., Frey et al., 2008; Saur et al., 2008; Catani and Mesulam, 2008; Makris and Pandya, 2009). In contrast, the functional involvement of the right hemisphere perisylvian network is yet less clear. Catani and colleagues suggested that the perisylvian network in the human right hemisphere might represent – as in the human left hemisphere – a network involved in language functions (Catani et al. 2007, p.17166). In this chapter, a different view is suggested. The perisylvian pathways between the right IPL, ventrolateral frontal, and superior/middle temporal cortices and insula connect those areas which have repeatedly been associated with spatial neglect in the case of brain damage (Heilman et al., 1983; Vallar and Perani, 1986; Mort et al., 2003; Karnath et al., 2001, 2004; Committeri et al., 2007; Sarri et al., 2009). In contrast, aphasia is only extremely rarely associated with lesion of these right hemisphere perisylvian areas (as rarely as spatial neglect is observed after left hemisphere damage). Thus, it is proposed that the perisylvian network in the human right hemisphere represents the anatomical basis for processes involved in spatial orienting and exploration.

Supporting evidence for this hypothesis has been reported from transcranial magnetic stimulation (TMS), electrical mapping of the human cortex during neurosurgery, and fMRI in

healthy subjects. Using TMS, Ellison and co-workers (2004) induced “virtual lesions” at the right STG and right posterior parietal cortex (PPC) in healthy subjects. They observed a specific impairment induced by TMS over the right STG for serial feature search (termed “hard feature search task”). In contrast, TMS over the right PPC resulted in increased reaction times during “hard conjunction search”. Gharabaghi and colleagues (2006) observed that intraoperative inactivation of the middle portion of the STG in human leads to disturbed serial visual search. Using the same technique Thiebaut de Schotten and colleagues (2005) found that inactivating regions in the right IPL or at the caudal and the middle parts of the STG leads to deficits in the perception of line length.

Evidence for the involvement of superior temporal, inferior parietal and ventrolateral frontal areas in processes of spatial orienting has also been obtained from fMRI experiments in healthy subjects. In a cued spatial-attention task, Hopfinger and co-workers (2000) found bilateral activation in these cortical areas correlated with covert attentional shifts in the horizontal dimension of space. Himmelbach and colleagues (2006) investigated active visual exploration in healthy subjects, using a task that closely resembled clinical procedures (visual search in a letter array) known to be particularly sensitive to neglect patients’ behavioral bias. The authors observed significant activation associated with visual exploration located at the TPJ, the mid-portion of the STG, and the IFG.

Thus, observations deriving from different techniques converge to suggest that the densely interconnected perisylvian neural system in the human right hemisphere (Fig. 17.2) represents the anatomical basis of those processes involved in spatial orientation, provoking spatial neglect in the case of damage. The tight anatomical connectivity between superior/middle temporal, inferior parietal and ventrolateral frontal cortices might explain why lesions at these distant cortical sites around the sylvian fissure in the human right hemisphere can lead to the same disturbance of orienting behavior, namely to spatial neglect.

Spatial neglect – a disconnection syndrome?

Beginning with the seminal work of Dejerine and his wife (Dejerine and Dejerine-Klumpke 1895) on the human cortical pathways, several authors developed the idea that some neurological conditions might result from the disconnection of one area of the brain from another. Among them, Geschwind (1965) put forward the view that several neuropsychological disorders could best be interpreted as resulting from interruption of specific cortical association pathways. With respect to spatial neglect Mesulam and

Geschwind (1978) suggested that this disorder – among other disorders of attention and emotion – results from disruption of neural connections between limbic structures and neocortex. Mesulam (1981, 1985) further evolved this concept suggesting that an interconnected network between posterior parietal, frontal, and cingulate cortices as well as the reticular formation is involved in spatial neglect. A disconnection hypothesis has also been put forward by Watson and colleagues (1974, 1978) when observing that spatial neglect can be evoked in the monkey by a lesion in the mesencephalic reticular formation.

More recently, some authors have revived the concept to view spatial neglect as a 'disconnection syndrome' (Catani, 2006; Bartolomeo et al., 2007; He et al., 2007). Bartolomeo and colleagues proposed that long-lasting signs of spatial neglect result from frontoparietal intrahemispheric and from interhemispheric disconnection. They suggested that 'a particular form of disconnection might have greater predictive value than the localization of gray matter lesions concerning the patients' deficits and disabilities (Bartolomeo et al., 2007, p. 2484)'. Intrahemispherically, they related disconnection of the SLF (Thiebaut de Schotten et al., 2005, 2008; Bartolomeo et al., 2007) but also of the IOF (Urbanski et al., 2008) to spatial neglect. Using DTI tractography, He and colleagues (2007) found damage to the SLF and AF in five patients with severe but not in five patients with mild spatial neglect. Furthermore, the analysis of interregional functional connectivity, based on coherent fluctuations of fMRI signals, suggested that not only anatomically but also functionally disrupted connectivity in dorsal and ventral attention networks might constitute a critical mechanism underlying the pathophysiology of spatial neglect (He et al., 2007).

To investigate the possible impact of damage to white matter association fibers for the genesis of spatial neglect, Karnath and co-workers (2009) analysed lesion location in a large 7-years sample of 140 right-hemispheric stroke patients. This large number of stroke patients allowed the authors not only to study a representative sample of subjects with spatial neglect, but also to perform a statistical voxelwise lesion-behavior mapping (VLBM) analysis (e.g., Bates et al., 2003; Rorden et al., 2007) to estimate which brain regions are more frequently compromised in neglect patients relative to patients without neglect. Karnath and co-workers (2009) studied the patients' white matter connectivity by using a new method which combines a statistical VLBM approach with the histological maps of the human white matter fiber tracts provided by the stereotaxic probabilistic atlas developed by the Jülich group (Amunts and Zilles, 2001; Zilles et al., 2002). In contrast to the reference brain of the Talairach and Tournoux atlas (Talairach and Tournoux 1988), or the MNI single subject or group templates (Evans et al., 1992; Collins et al., 1994), the Jülich probabilistic atlas is based on the analysis

of the cytoarchitecture in a sample of ten different human post-mortem brains. It thus provides information on the location and intersubject variability of brain structures, illustrating for each voxel of the MNI reference space the relative frequency with which a certain structure was present in ten normal human brains. Using a modified myelin staining technique Bürgel and colleagues (2006) were able to distinguish ten individual white matter fiber tracts for this atlas at microscopic resolution.

The analysis of the 140 right hemisphere stroke patients revealed that 7.0% of the right SLF, 8.2% of the IOF, 12.7% of the SOF, and only 0.6% of the uncinate fasciculus were significantly more affected in patients with spatial neglect than in those not showing the disorder (Fig. 17.3). The authors concluded that damage of right perisylvian white matter connections is a typical finding in patients with spatial neglect. However, the proportion of involvement of each of the fiber bundles was very low. When the authors analysed how much of the lesion area in neglect patients overlapped with all of the perisylvian white matter connections, they found an overlap between 3.4% and 10.9% (Karnath et al., 2009).

----- Figure 17.3 around here -----

Although the study of Karnath and co-workers (2009) cannot finally decide whether or not spatial neglect should best be interpreted as a 'disconnection syndrome' (Mesulam and Geschwind 1978; Watson et al., 1974, 1978; Catani, 2006; Bartolomeo et al., 2007; He et al., 2007) one may conclude that their data argue more against than in favour of such a hypothesis. In fact, their analysis revealed that between 89.1% and 96.6% of the lesion area in spatial neglect affected brain structures other than the perisylvian white matter fiber tracts, namely cortical and subcortical gray matter structures such as the superior temporal, inferior parietal, inferior frontal, and insular cortices, as well as the putamen and caudate nucleus (Karnath et al., 2009). Damage to these gray matter structures in the right hemisphere thus appears to be a strong predictor of spatial neglect.

Another aspect arguing against the view of spatial neglect as a white matter disconnection syndrome in the traditional sense are the perfusion-weighted imaging (PWI) results obtained in patients with subcortical infarcts. PWI is a MR technique that allows the identification of brain regions that are receiving enough blood supply to remain structurally intact, but not enough to function normally. By using this technique several studies showed that left- or right-sided subcortical lesions – including selective white matter strokes – cause spatial neglect only if the subcortical damage provokes additional malperfusion of cortical

gray matter structures in the ipsilesional hemisphere (Demeurisse et al., 1997; Hillis et al., 2002, 2005). Without this malfunction of cortical structures subcortical brain lesions did not provoke disturbances of spatial orienting. Thus, it seems that damage of subcortical white matter connectivity alone does not provoke spatial neglect but rather requires additional involvement of cortical gray matter structures.

Conclusions

Homologous perisylvian neural networks seem to exist in the human left and right hemispheres composed of tightly connected cortical areas straddling the sylvian fissure (cf. Fig. 17.2). It is suggested that the neural network consisting of superior/middle temporal, inferior parietal, and ventrolateral frontal cortices in the human right hemisphere represents the anatomical basis for processes involved in spatial orienting. Neurons of these regions provide us with redundant information about the position and motion of our body in space. They seem to play an essential role in adjusting body position relative to external space (Karnath and Dieterich, 2006). Damage to this perisylvian system in the right hemisphere may provoke spatial neglect. In the human left hemisphere, a similar perisylvian network seems to exist but is serving different functions, namely language and praxis. This functional specialisation of left and right perisylvian networks is still not observed in the non-human primate. Here, lesions of this perisylvian system in both hemispheres induce disturbed exploration and orientation towards the respective contralateral side (e.g., Luh et al., 1986; Watson et al., 1994; Wardak et al., 2002, 2004). Hence, the phylogenetic transition from monkey to human brain seems to be a restriction of a formerly bilateral function represented within right- and left-sided perisylvian networks to the right hemisphere (Karnath et al., 2001). It appears as if this lateralization of spatial orientation to the right hemisphere network parallels the emergence of an elaborate representation for language in the left-sided perisylvian network.

References

- Amunts, K., and K. Zilles, 2001. Advances in cytoarchitectonic mapping of the human cerebral cortex. *Neuroimaging Clin. N. Am.* 11:151–169.
- Bartolomeo, P., M. Thiebaut de Schotten, and F. Doricchi, 2007. Left unilateral neglect as a disconnection syndrome. *Cerebr. Cortex* 17: 2479-2490.
- Bates, E., S. M. Wilson, A. P. Saygin, F. Dick, M. I. Sereno, R. T. Knight, and N. F. Dronkers, 2003. Voxel-based lesion–symptom mapping. *Nat. Neurosci.* 6:448-450.
- Behrmann, M., S. Watt, S. E. Black, and J. J. Barton, 1997. Impaired visual search in patients with unilateral neglect: an oculographic analysis. *Neuropsychologia* 35:1445-1458.
- Boatman, D., 2004. Cortical bases of speech perception: evidence from functional lesion studies. *Cognition* 92:47-65.
- Borovsky, A., A. P. Saygin, E. Bates, and N. Dronkers, 2007. Lesion correlates of conversational speech production deficits. *Neuropsychologia* 45:2525-2533.
- Bürgel, U., K. Amunts, L. Hoemke, H. Mohlberg, J. M. Gilsbach, and K. Zilles, 2006. White matter fiber tracts of the human brain: three-dimensional mapping at microscopic resolution, topography and intersubject variability. *Neuroimage* 29: 1092-1105.
- Burdach, K.F., 1819–1826. *Vom Baue und Leben des Gehirns*. Leipzig: Dyk.
- Buxbaum, L.J., M. K. Ferraro, T. Veramonti, A. Farne, J. Whyte, E. Ladavas, F. Frassinetti, and H. B. Coslett, 2004. Hemispatial neglect: subtypes, neuroanatomy, and disability. *Neurology* 62: 749-756.
- Catani, M., 2006. Diffusion tensor magnetic resonance imaging tractography in cognitive disorders. *Curr. Opin. Neurol.* 19: 599–606.
- Catani, M., and M. Mesulam, 2008. The arcuate fasciculus and the disconnection theme in language and aphasia: history and current state. *Cortex* 44:953-961.
- Catani, M., R. J. Howard, S. Pajevic, and D. K. Jones, 2002. Virtual in vivo interactive dissection of white matter fasciculi in the human brain. *Neuroimage* 17: 77-94.
- Catani, M., D. K. Jones, and D. H. ffytche, 2005. Perisylvian language networks of the human brain. *Ann. Neurol.* 57: 8-16.
- Catani M., M. P. G. Allin, M. Husain, L. Pugliese, M.-M. Mesulam, R. M. Murray, and D. K. Jones, 2007. Symmetries in human brain language pathways correlate with verbal recall. *Proc. Natl. Acad. Sci. USA* 104: 17163-17168.

- Collins, D.L., P. Neelin, T. M. Peters, and A. C. Evans, 1994. Automatic 3D intersubject registration of MR volumetric data in standardized Talairach space. *J. Comput. Assist. Tomogr.* 18:192–205.
- Committeri, G., S. Pitzalis, G. Galati, F. Patria, G. Pelle, U. Sabatini, A. Castriota-Scanderbeg, L. Piccardi, C. Guariglia, and L. Pizzamiglio, 2007. Neural bases of personal and extrapersonal neglect in humans. *Brain* 130: 431-441.
- Corbetta, M., M. J. Kincade, C. Lewis, A. Z. Snyder, and A. Sapir, 2005. Neural basis and recovery of spatial attention deficits in spatial neglect. *Nat. Neurosci.* 8: 1603-1610.
- Dejerine, J, and A. M. Dejerine-Klumpke, 1895. *Anatomie Des Centres Nerveux*. Paris: Rueff et Cie.
- Demeurisse, G., C. Hublet, J. Paternot, C. Colson, and W. Serniclaes, 1997. Pathogenesis of subcortical visuo-spatial neglect. A HMPAO SPECT study. *Neuropsychologia* 35:731-735.
- Dronkers, N. F., D. P. Wilkins, R. D. Van Valin Jr., B. B. Redfern, and J. J. Jaeger, 2004. Lesion analysis of the brain areas involved in language comprehension. *Cognition* 92:145-177.
- Duffau, H., P. Gatigno, E. Mandonnet, P. Peruzzi, N. Tzourio-Mazoyer, and L. Capelle, 2005. New insights into the anatomo-functional connectivity of the semantic system: a study using cortico-subcortical electrostimulations. *Brain* 128: 797–810.
- Ellison, A., I. Schindler, L. L. Pattison, A. D. Milner, 2004. An exploration of the role of the superior temporal gyrus in visual search and spatial perception using TMS. *Brain* 127: 2307-2315.
- Evans, A.C., S. Marrett, P. Neelin, L. Collins, K. Worsley, W. Dai, S. Milot, E. Meyer, and D. Bub, 1992. Anatomical mapping of functional activation in stereotactic coordinate space. *Neuroimage* 1:43– 53.
- Frey, S., J. S. Campbell, G. B. Pike, and M. Petrides, 2008. Dissociating the human language pathways with high angular resolution diffusion fiber tractography. *J. Neurosci.* 28:11435-11444.
- Fruhmann-Berger, M., and H.-O. Karnath H-O, 2005. Spontaneous eye and head position in patients with spatial neglect. *J. Neurol.* 252: 1194-1200.
- Fruhmann Berger, M., R. D. Proß, U. J. Ilg, and H.-O. Karnath, 2006. Deviation of eyes and head in acute cerebral stroke. *BMC Neurology* 6: 23, Corrigendum 6: 49.

Gharabaghi, A., M. Fruhmann Berger, M. Tatagiba, and H.-O. Karnath, 2006. The role of the right superior temporal gyrus in visual search – insights from intraoperative electrical stimulation. *Neuropsychologia* 44: 2578-2581, Corrigendum 45:465.

Gharabaghi, A., F. Kunath, M. Erb, R. Saur, S. Heckl, M. Tatagiba, W. Grodd, and H.-O. Karnath, 2009. Perisylvian white matter connectivity in the human right hemisphere. *BMC Neurosci.* 10: 15.

Glasser, M. F., and J. K. Rilling, 2008. DTI tractography of the human brain's language pathways. *Cerebr. Cortex* 18: 2471-2482.

Geschwind, N., 1965. Disconnexion syndromes in animals and man. *Brain* 88: 237-294, 585-644.

Goldenberg, G., and H.-O. Karnath, 2006. The neural basis of imitation is body part specific. *J. Neurosci.* 26: 6282-6287.

Goldenberg, G., J. Hermsdörfer, R. Glindemann, C. Rorden, and H.-O. Karnath, 2007. Pantomime of tool use depends on integrity of left inferior frontal cortex. *Cerebr. Cortex* 17: 2769-2776.

He, B. J., A. Z. Snyder, J. L. Vincent, A. Epstein, G. L. Shulman, and M. Corbetta, 2007. Breakdown of functional connectivity in frontoparietal networks underlies behavioral deficits in spatial neglect. *Neuron* 53: 905-918.

Heilman, K. M., R. T. Watson, E. Valenstein, and A. R. Damasio, 1983. Localization of lesions in neglect. In: Kertesz, A., editor. *Localization in Neuropsychology*. New York: Academic Press, pp. 471-492.

Hillis, A.E., R. J. Wityk, P. B. Barker, N. J. Beauchamp, P. Gailloud, K. Murphy, O. Cooper, and E. J. Metter, 2002. Subcortical aphasia and neglect in acute stroke: the role of cortical hypoperfusion. *Brain* 125: 1094-1104.

Hillis, A. E., M. Newhart, J. Heidler, P. B. Barker, E. H. Herskovits, M. Degaonkar, 2005. Anatomy of spatial attention: insights from perfusion imaging and hemispatial neglect in acute stroke. *J. Neurosci.* 25:3161-3167.

Himmelbach, M., M. Erb, and H.-O. Karnath, 2006. Exploring the visual world: the neural substrate of spatial orienting. *Neuroimage* 32:1747-1759.

Hopfinger, J.B., M. H. Buonocore, and G. R. Mangun, 2000. The neural mechanisms of top-down attentional control. *Nat. Neurosci.* 3: 284-91.

Husain, M., and C. Kennard, 1996. Visual neglect associated with frontal lobe infarction. *J. Neurol.* 243: 652-657.

Iacoboni, M., and S. M. Wilson, 2006. Beyond a single area: motor control and language within a neural architecture encompassing Broca's area. *Cortex* 42: 503-506.

Karnath, H.-O., and M. Dieterich, 2006. Spatial neglect – a vestibular disorder? *Brain* 129: 293-305.

Karnath, H.-O., M. Niemeier, and J. Dichgans, 1998. Space exploration in neglect. *Brain* 121: 2357-2367.

Karnath, H.-O., S. Ferber, and M. Himmelbach, 2001. Spatial awareness is a function of the temporal not the posterior parietal lobe. *Nature* 411: 950-953.

Karnath, H.-O., M. Fruhmann Berger, W. Küker, and C. Rorden, 2004. The anatomy of spatial neglect based on voxelwise statistical analysis: a study of 140 patients. *Cerebr. Cortex* 14: 1164-1172.

Karnath, H.-O., C. Rorden, and L. F. Ticini, 2009. Damage to white matter fiber tracts in acute spatial neglect. *Cerebr. Cortex* 19: 2331-2337.

Kertesz, A., W. Harlock, and R. Coates, 1979. Computer tomographic localization, lesion size, and prognosis in aphasia and nonverbal impairment. *Brain and Language* 8:34-50.

Kier E.L., L. H. Staib , L. M. Davis, and R. A. Bronen, 2004. MR Imaging of the Temporal Stem: Anatomic Dissection Tractography of the Uncinate Fasciculus, Inferior Occipitofrontal Fasciculus, and Meyer's Loop of the Optic Radiation. *Am. J. Neuroradiol.* 25:677-691.

Kreisler, A., O. Godefroy, C. Delmaire, B. Debachy, M. Leclercq, J.-P. Pruvo, and D. Leys, 2000. The anatomy of aphasia revisited. *Neurology* 54:1117-1123.

Luh, K. E., C. M. Butter, and H. A. Buchtel, 1986. Impairments in orienting to visual stimuli in monkeys following unilateral lesions of the superior sulcal polysensory cortex. *Neuropsychologia* 24:461-470.

Makris, N., and D. N. Pandya, 2009. The extreme capsule in humans and rethinking of the language circuitry. *Brain Struct. Funct.* 213:343-358.

Makris, N., D. N. Kennedy, S. McInerney, A. G. Sorensen, R. Wang, V. S. Caviness Jr., and D. N. Pandya, 2005. Segmentation of subcomponents within the superior longitudinal fascicle in humans: a quantitative, in vivo, DT-MRI study. *Cerebr. Cortex* 15: 854–869.

- Makris, N., G. M. Papadimitriou, S. Sorg, D. N. Kennedy, V. S. Caviness, and D. N. Pandya, 2007. The occipitofrontal fascicle in humans: a quantitative, in vivo, DT-MRI study. *Neuroimage* 37: 1100-1111.
- Makris, N., G. M. Papadimitriou, J. R. Kaiser, S. Sorg, D. N. Kennedy, and D. N. Pandya, 2009. Delineation of the Middle Longitudinal Fascicle in Humans: A Quantitative, In Vivo, DT-MRI Study. *Cerebr. Cortex* 19: 777-785.
- Mesulam, M.-M., 1981. A cortical network to directed attention and unilateral neglect. *Ann. Neurol.* 10: 309-325.
- Mesulam, M.-M., 1985. Attention, confusional states, and neglect. In: Mesulam, M.-M., ed. *Principles of behavioral neurology*. Philadelphia: F. A. Davis, 125-168.
- Mesulam, M.-M., and N. Geschwind, 1978. On the possible role of neocortex and its limbic connections in the process of attention and schizophrenia: clinical cases of inattention in man and experimental anatomy in monkey. *J. Psychiat. Res.* 14: 249-259.
- Mori, S., S. Wakana, P. C. M. van Zijl, and L. M. Nagele-Poetscher, 2005. *MRI atlas of human white matter*. Amsterdam: Elsevier.
- Mort, D. J., P. Malhotra, S. K. Mannan, C. Rorden, A. Pambakian, C. Kennard, and M. Husain, 2003. The anatomy of visual neglect. *Brain* 126: 1986-1997.
- Nieuwenhuys, R., J. Voogd, and C. van Huijzen, 1988. *The Human Central Nervous System*. Berlin: Springer.
- Petrides, M., and D. N. Pandya, 1984. Projections to the frontal cortex from the posterior parietal region in the rhesus monkey. *J. Comp. Neurol.* 228: 105-116.
- Petrides, M., and D. N. Pandya, 1988. Association fiber pathways to the frontal cortex from the superior temporal region in the rhesus monkey. *J. Comp. Neurol.* 273: 52-66.
- Petrides, M., and D. N. Pandya, 2007. Efferent association pathways from the rostral prefrontal cortex in the macaque monkey. *J. Neurosci.* 27:11573-11586.
- Poeck, K., R. de Bleser, and D. Graf von Keyserlingk, 1984. Computed tomography localization of standard aphasic syndromes. In: Rose, F. C., ed. *Advances in Neurology*, Vol. 42: Progress in Aphasiology. New York: Raven Press, pp. 71-89.
- Powell, H. W. R., G. J. M. Parker, D. C. Alexander, M. R. Symms, P. A. Boulby, C. A. M. Wheeler-Kingshott, G. J. Barker, U. Noppeney, M. J. Koepp, and J. S. Duncan, 2006. Hemispheric asymmetries in language-related pathways: A combined functional MRI and tractography study. *Neuroimage* 32: 388-399.

- Rizzolatti, G., and M. A. Arbib, 1998. Language within our grasp. *Trends Neurosci.* 21:188–194.
- Rorden, C., H.-O. Karnath, and L. Bonilha, 2007. Improving lesion-symptom mapping. *J. Cogn. Neurosci.* 19: 1081-1088.
- Sanai, N., Z. Mirzadeh, M. S. Berger, 2008. Functional outcome after language mapping for glioma resection. *N. Engl. J. Med.* 358: 18-27.
- Sarri, M., R. Greenwood, L. Kalra, J. Driver, 2009. Task-related modulation of visual neglect in cancellation tasks. *Neuropsychologia* 47:91-103.
- Saur, D., B. W. Kreher, S. Schnell, D. Kümmerer, P. Kellmeyer, M. S. Vry, R. Umarova, M. Musso, V. Glauche, S. Abel, W. Huber, M. Rijntjes, J. Hennig, and C. Weiller, 2008. Ventral and dorsal pathways for language. *Proc. Natl. Acad. Sci. USA* 105:18035-18040.
- Schmahmann, J. D., and D. N. Pandya, 2006. *Fiber pathways of the brain*. New York: Oxford University Press.
- Schmahmann, J. D., D. N. Pandya, R. Wang, G. Dai, H. E. D’Arceuil, A. J. de Crespigny, and V. J. Wedeen, 2007. Association fiber pathways of the brain: parallel observations from diffusion spectrum imaging and autoradiography. *Brain* 130: 630-653.
- Seltzer, B., and D. N. Pandya, 1984. Further observations on parieto-temporal connections in the rhesus monkey. *Exp. Brain Res.* 55: 301–12.
- Talairach, J., and P. Tournoux, 1988. *Co-Planar Stereotaxic Atlas of the Human Brain*. Stuttgart: Thieme.
- Thiebaut de Schotten, M., M. Urbanski, H. Duffau, E. Volle, R. Lévy, B. Dubois, and P. Bartolomeo, 2005. Direct evidence for a parietal-frontal pathway subserving spatial awareness in humans. *Science* 309: 2226-2228.
- Thiebaut de Schotten, M., S. Kinkingnéhun, C. Delmaire, S. Lehericy, H. Duffau, L. Thivard, E. Volle, R. Lévy, B. Dubois, and P. Bartolomeo, 2008. Visualization of disconnection syndromes in humans. *Cortex* 44:1097-1103.
- Upadhyay, J., K. Hallock, M. Ducros, D.-S. Kim, and I. Ronen, 2008. Diffusion tensor spectroscopy and imaging of the arcuate fasciculus. *Neuroimage* 39: 1-9.
- Urbanski, M., M. Thiebaut de Schotten, S. Rodrigo, M. Catani, C. Oppenheim, E. Touzé, S. Chokron, and J.-F. Méder, R. Lévy, B. Dubois, and P. Bartolomeo, 2008. Brain networks of

spatial awareness: evidence from diffusion tensor imaging tractography. *J. Neurol. Neurosurg. Psychiatry* 79: 598-601.

Vallar, G., and D. Perani, 1986. The anatomy of unilateral neglect after right-hemisphere stroke lesions. A clinical/CT-scan correlation study in man. *Neuropsychologia* 24: 609-6

Vernooij, M. W., M. Smits, P. A. Wielopolski, G. C. Houston, G. P. Krestin, and A. van der Lugt, 2007. Fiber density asymmetry of the arcuate fasciculus in relation to functional hemispheric language lateralization in both right- and left-handed healthy subjects: a combined fMRI and DTI study. *Neuroimage* 35: 1064–1076.

Vigneau, M., V. Beaucousin, P.Y. Herve', H. Duffau, F. Crivello, O. Houde', B. Mazoyer, and N. Tzourio-Mazoyer, 2006. Meta-analyzing left hemisphere language areas: Phonology, semantics, and sentence processing. *Neuroimage* 30:1414–1432.

Wakana S., H. Jiang, L. M. Nagae-Poetscher, P. C. M. van Zijl, and S. Mori, 2004. Fiber Tract-based Atlas of Human White Matter Anatomy. *Radiology* 230:77-87.

Wardak, C., E. Olivier, and J.-R. Duhamel, 2002. Neglect in monkeys: effect of permanent and reversible lesions. In: Karnath, H.-O., A. D. Milner, and G. Vallar, eds. *The Cognitive and Neural Bases of Spatial Neglect*. Oxford: Oxford University Press, pp. 101-118.

Wardak, C., E. Olivier, and J.-R. Duhamel, 2004. A deficit in covert attention after parietal cortex inactivation in the monkey. *Neuron*, 42:501–508.

Watson, R. T., K. M. Heilman, B. D. Miller, and F. A. King, 1974. Neglect after mesencephalic reticular formation lesions. *Neurology* 24:294-298.

Watson, R. T., B. D. Miller, and K. M. Heilman, 1978. Nonsensory neglect. *Ann. Neurol.* 3:505-508.

Watson, R. T., E. Valenstein, A. Day, and K. M. Heilman, 1994. Posterior neocortical systems subserving awareness and neglect. *Arch. Neurol.* 51:1014-1021.

Zilles, K., A. Schleicher, N. Palomero-Gallagher, and K. Amunts K, 2002. Quantitative analysis of cyto- and receptor architecture of the human brain. In: Mazziotta, J. C., and A. Toga, editors. *Brain Mapping: The Methods*. Amsterdam: Elsevier, pp. 573– 602.

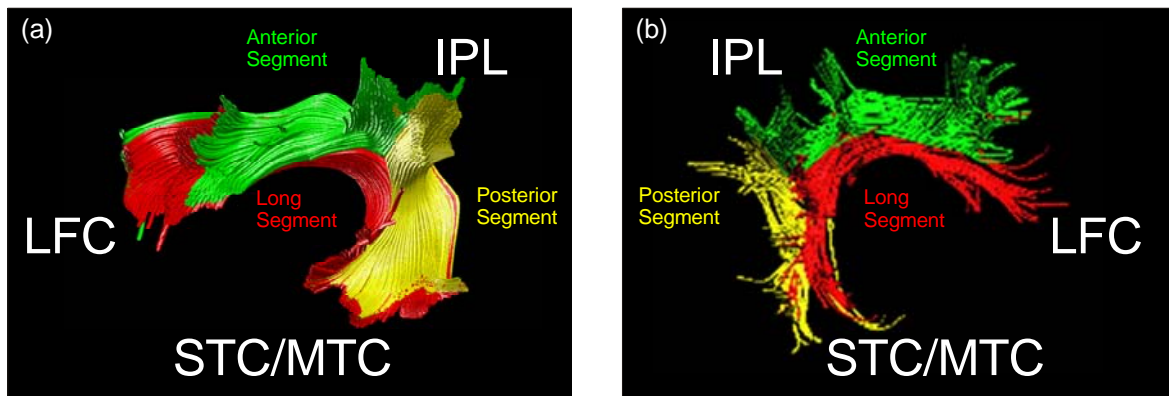


Figure 17.1

Averaged tractography reconstruction for fiber connections between the superior/middle temporal, inferior parietal, and dorsolateral frontal cortices by using a two-region of interest approach in (a) the human left hemisphere (Catani et al., 2005) and (b) the human right hemisphere (Gharabaghi et al., 2009). A long connection was observed linking superior/middle temporal and dorsolateral frontal cortices (shown in red). Two shorter pathways also were found. The posterior segment running from the superior/middle temporal to the inferior parietal cortex is shown in yellow. The anterior segment running from the inferior parietal to the dorsolateral frontal cortex is shown in green. IPL, inferior parietal lobule; DFC, dorsolateral frontal cortex; STC, superior temporal cortex; MTC, middle temporal cortex. (With modifications from Catani et al., 2005, and from Gharabaghi et al., 2009). (See color plate 19).

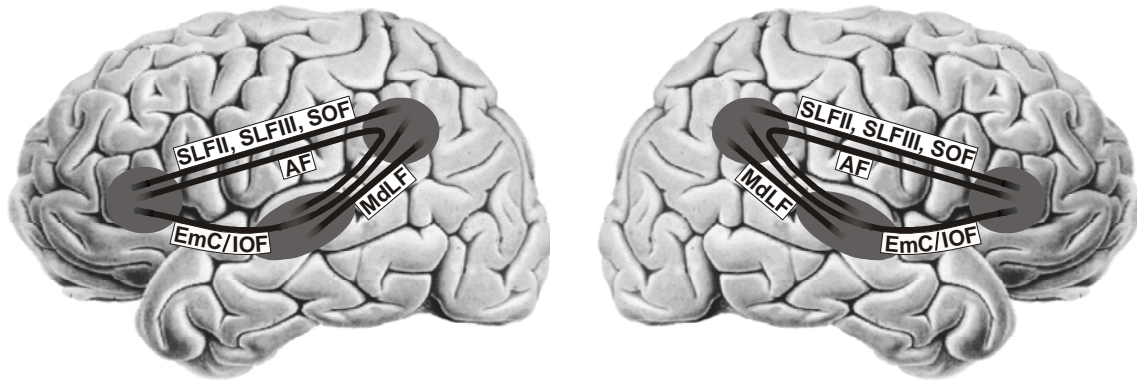

Figure 17.2

Sketch of the perisylvian neural network linking the inferior parietal lobule with the ventrolateral frontal cortex (via SLF II, SLF III, SOF), ventrolateral frontal cortex with superior/middle temporal cortex and insula (via AF, EmC/IOF), and superior temporal cortex with the inferior parietal lobule (via MdLF, EmC/IOF). SLF II/III, subcomponents II/III of the superior longitudinal fasciculus; SOF, superior occipitofrontal fasciculus; AF, arcuate fasciculus; EmC, extreme capsule; IOF, inferior occipitofrontal fasciculus; MdLF, middle longitudinal fasciculus.

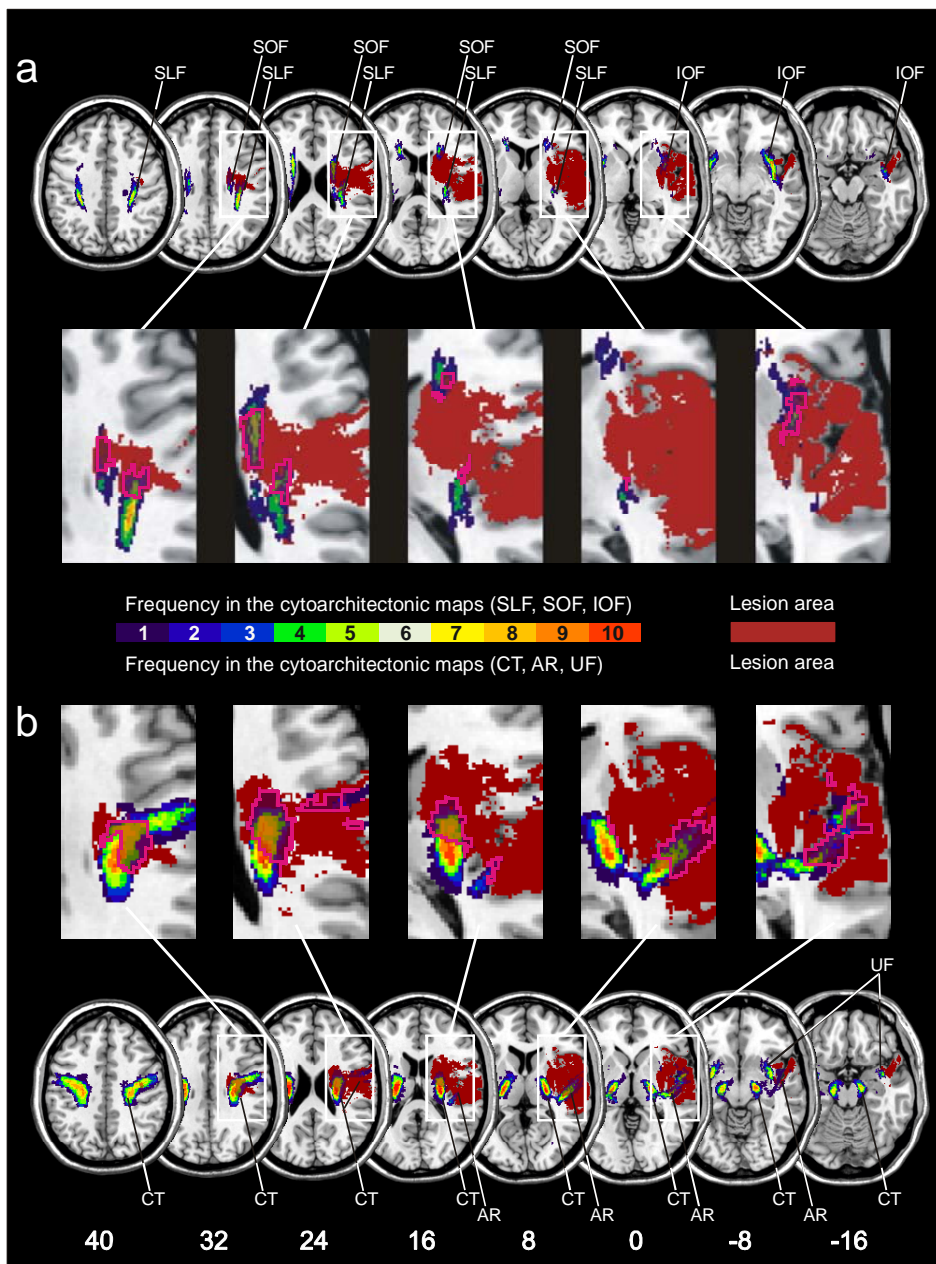


Figure 17.3

Overlap of the statistical VLBm lesion map (the brain territory significantly more affected in 78 patients with spatial neglect than in 62 stroke patients without this disorder) with the probabilistic, cytoarchitectonic maps of the white matter association fiber tracts from the Jülich atlas. The statistical lesion map is illustrated in homogenous brown color. The color coding of the Jülich atlas from 1 (dark blue, observed in 1 post-mortem brain) to 10 (red, overlap in all ten post-mortem brains) represents the absolute frequency for which in each voxel of the brain a respective fiber tract was present (e.g., yellow color indicates that the fiber tract was present in that voxel in seven out of ten post-mortem brains). The pink contour demarks the area of the fiber tracts affected by the statistical lesion map. (a) Overlap illustrated for perisylvian fiber tracts SFL = superior longitudinal fasciculus, IOF = inferior occipitofrontal fasciculus, and SOF = superior occipitofrontal fasciculus. (b) Overlap illustrated for fiber tracts CT = corticospinal tract, AR = acoustic radiation, and UF = uncinate fascicle. (From Karnath et al., 2009). (See color plate 20).

Acknowledgements

This work was supported by the Bundesministerium für Bildung und Forschung (BMBF-Verbundprojekt "Räumliche Orientierung" 01GW0641) and the Deutsche Forschungsgemeinschaft (SFB 550-A4). I would like to thank Bianca de Haan and Marc Himmelbach for their discussion and helpful comments on the manuscript.